



**PATIENT**

Panda Cooney

**SPECIES**

Canine

**BREED**

German Shepherd

**SEX**

FS

**AGE**

3yr

**WEIGHT**

82lb

**INTERPRETED BY**

R. McKenzie Daniel,  
DVM, DABVP  
(Canine and Feline)

**IMAGING PERFORMED BY**

Shari Reffi CVT

**HOSPITAL NAME**

Pet Stat Animal Urgent  
Care

**REFERRING VET**

Dr Doug Payne

**INVOICE**  
23935

**DATE**  
02/19/2026

**PRESENTING CLINICAL SIGNS**

- BCS 5/9
- Mid abdominal organomegaly
- R/O Spleen (noted on abd rads 12/23/25) -Rads attached for reference
- Current Meds: Torb sedation for scan. , Gabapentin

Abnormal PE/Chem/CBC/UA Results: wn

**ULTRASONOGRAPHIC EXAMINATION OF THE ABDOMEN**

**Urinary System**

The urinary bladder, trigone, cystourethral junction, and visible pelvic urethra to a depth of 3 cm exhibited normal thickness and tone. Anechoic urine was present in the lumen with no evidence of urine/lumen sediment, mineral, or calculi. The ureteral papillae were normal. The ureters were not visible which is normal. No evidence of inflammatory or neoplastic changes was noted.

Normal size and margination were present in the kidneys. A normal 1:3 cortex / medulla ratio and normal corticomedullary definition were maintained. The echogenicity of the cortex was similar to or slightly less than normal liver parenchyma while the medulla echogenicity was hypoechoic to the cortex with no evidence of pelvic dilation. The left kidney measured 6.5 cm in length. The right kidney measured 6.5 cm in length.

The area of the aortic trifurcation was free of pathology.

**Adrenal Glands**

The left adrenal gland was uniform in size and contour with a uniformly hypoechoic parenchyma. The left adrenal gland measured 0.59 cm width at the caudal pole. The right adrenal gland was uniform in size and contour with a uniformly hypoechoic parenchyma. The right adrenal gland measured 0.68 cm width at the caudal pole.

**Spleen**

The spleen exhibited generalized splenomegaly with splenic folding. Symmetrical contour and homogenous parenchyma were maintained. Normal splenic vascularity. No visualized masses or nodules were present.

**Liver/Gallbladder**

The liver was subjectively normal in size, structure, and contour. The liver parenchyma was uniform and hypoechoic to the spleen with a mild coarse echotexture. Normal vascular volume. The hepatic and portal vasculature were normal in appearance without signs of congestion. The gallbladder was non-distended in size with thin walls and primarily anechoic luminal content. The cystic and common bile ducts were normal.

**Gastrointestinal**

The stomach presented intact wall layering with a normal wall layer ratio. The lumen of the stomach was empty with no signs of ileus, obstruction or foreign material.



**PATIENT**

Panda Cooney

The small intestine presented intact wall layering with 1:3 muscularis/mucosa ratio. The lumen of the small intestine was empty with no signs of mechanical/metabolic ileus, obstruction or foreign material.

Normal visible colon wall layers were present with apparent formed feces in lumen.

**SPECIES**

Canine

***Pancreas***

The parenchyma of the left limb, body and right limb of the pancreas presented isoechoic to the adjacent omental fat. A normal curvilinear capsule contour of the pancreas was present. The visible pancreatic duct was normal. No signs of active inflammation or neoplastic disease was evident.

**BREED**

German Shepherd

***Free Abdomen***

No omental masses, overt lymphadenopathy or peritoneal effusion was present.

**SEX**

FS

Rapid view of the heart revealed no evidence of pericardial masses or effusion in the visible window.

**ULTRASONOGRAPHIC FINDINGS**

**Primary**

**AGE**

3yr

- Enlarged folded spleen

**INTERPRETATION OF THE FINDINGS & FURTHER RECOMMENDATIONS**

**WEIGHT**

82lb

Breed associated hypersplenism is suspected with splenic hyperplasia, hematopoiesis or inflammation possible. Splenic neoplasia thought less likely. Assuming normal clotting status, using a 25ga needle, splenic FNA cytology is warranted for further clarification. Aside from the suspect benign splenomegaly, no evidence of additional abdominal visceral pathology.

**INTERPRETED BY**

R. McKenzie Daniel,  
DVM, DABVP  
(Canine and Feline)

**IMAGING  
PERFORMED BY**

Shari Reffi CVT

**HOSPITAL NAME**

Pet Stat Animal Urgent  
Care

**REFERRING VET**

Dr Doug Payne

**INVOICE**

23935

**DATE**

02/19/2026



**PATIENT**

Panda Cooney

**SPECIES**

Canine

**BREED**

German Shepherd

**SEX**

FS

**AGE**

3yr

**WEIGHT**

82lb

**INTERPRETED BY**

R. McKenzie Daniel,  
 DVM, DABVP  
 (Canine and Feline)

**IMAGING PERFORMED BY**

Shari Reffi CVT

**HOSPITAL NAME**

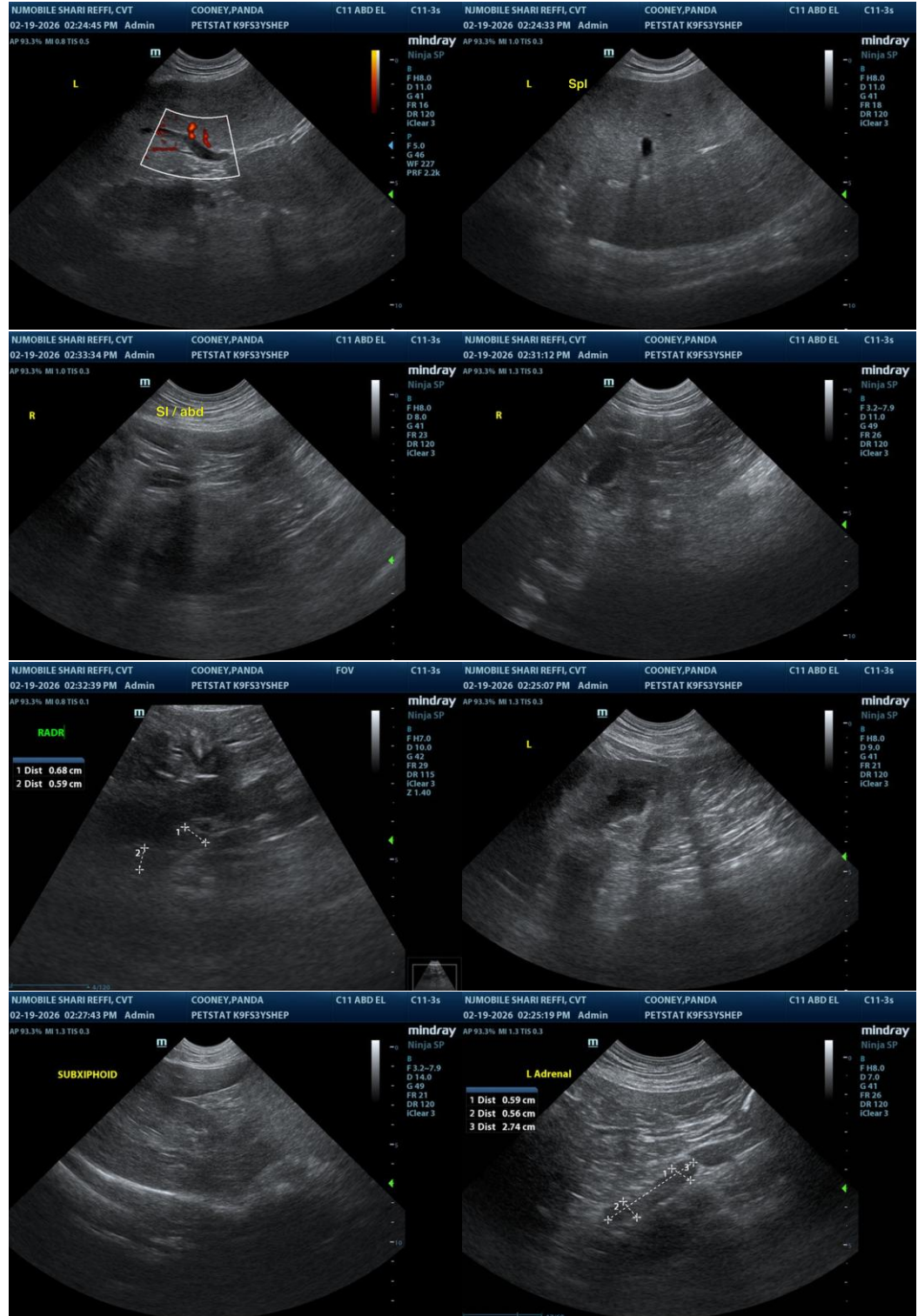
Pet Stat Animal Urgent  
 Care

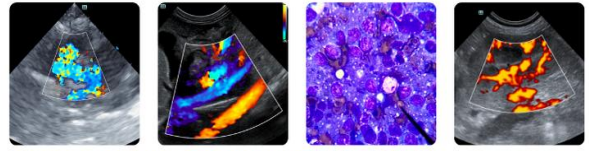
**REFERRING VET**

Dr Doug Payne

**INVOICE**  
 23935

**DATE**  
 02/19/2026





**PATIENT**

Panda Cooney

The information and recommendations provided are based on the images presented by the referring veterinarian/sonographer. No evaluation can be communicated regarding pathology that was not visible in the image/video clips provided.

**SPECIES**

Canine

Thank you for this referral. If the clinical or image interpretation does not parallel your findings or if I can be of any further assistance, please contact me.

**BREED**

German Shepherd

R. McKenzie Daniel, DVM, DABVP (Canine/Feline Practice)  
[info@sonopath.com](mailto:info@sonopath.com)

**SEX**

FS

**AGE**

3yr

**WEIGHT**

82lb

**INTERPRETED BY**

R. McKenzie Daniel,  
DVM, DABVP  
(Canine and Feline)

**IMAGING  
PERFORMED BY**

Shari Reffi CVT

**HOSPITAL NAME**

Pet Stat Animal Urgent  
Care

**REFERRING VET**

Dr Doug Payne

**INVOICE  
23935**

**DATE**  
02/19/2026